Sequestration

Mitchell Pearce D.O., Thomas Taylor M.D.

Arnot Ogden Medical Center, Diagnostic Radiology Department, Elmira, NY

ArnotHealth

LECOMT LAKE ERIE CONSORTIUM FOR OSTEOPATHIC MEDICAL TRAINING

INTRODUCTION

BACKGROUND: 34-year-old male presented to the ED with pelvic pain and a CT of the abdomen and pelvis was ordered for further workup. Incidentally found in the posterior right lung base was a well circumscribed region of increased lucency when compared to the remainder of the adjacent lung and left lung which was being fed by an artery which arose from the descending aorta at the T11-T12 level.

IMAGING

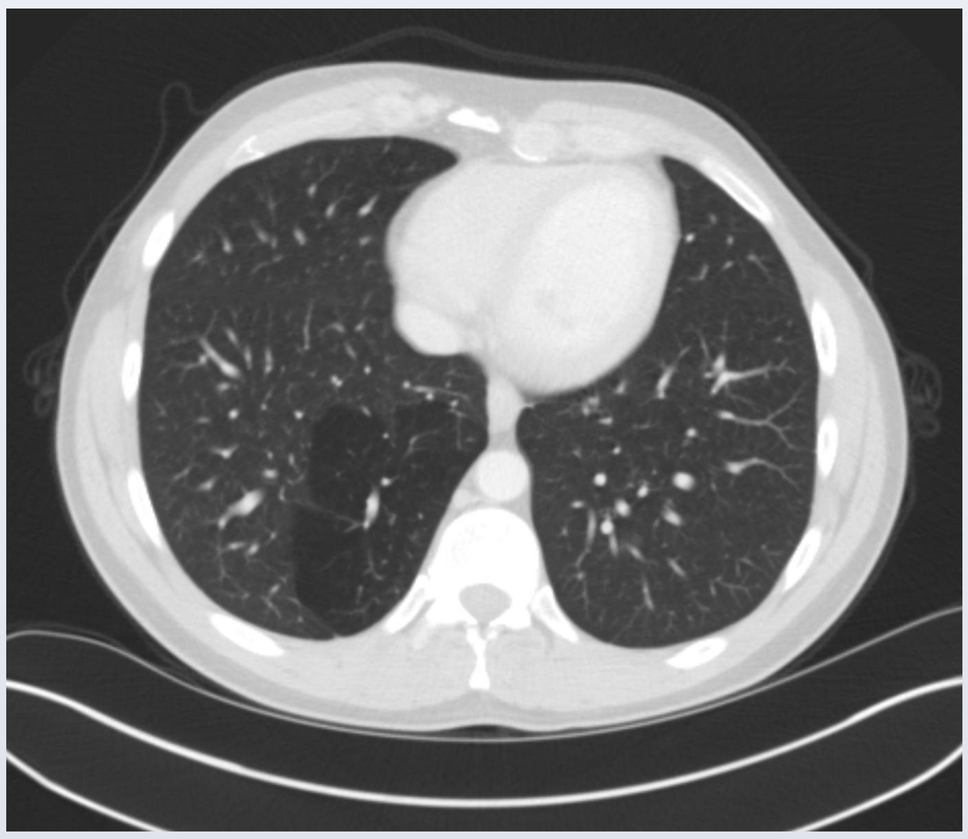

Axial CT of the lung bases with IV Contrast: Contrast enhanced CT at the lung bases show a well demarcated region of lucency in the posterior right lower lobe

Axial CT of the lung bases with IV Contrast: Contrast enhanced CT at the lung bases show the well demarcated region of lucency in the posterior right lower lobe to advantage with an enhancing feeding artery emanating from the aorta.

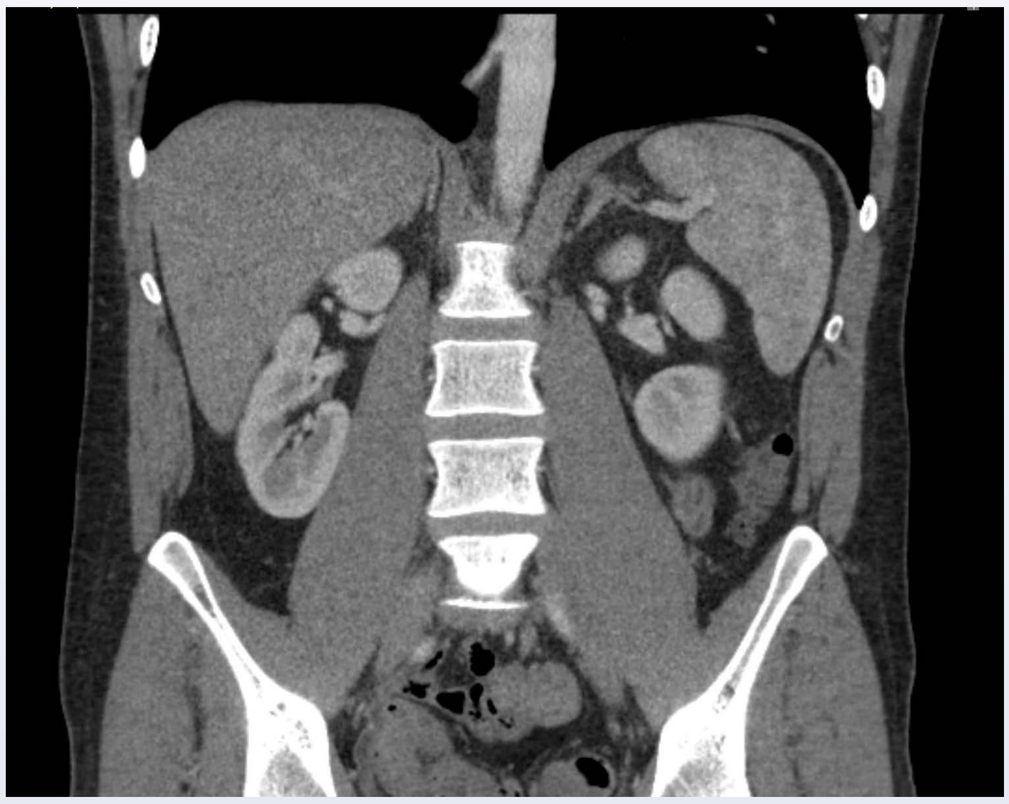

Coronal CT of the Abdomen: Single contrast enhanced coronal CT of the abdomen show the feeding vessel emanating form the aorta branching to the right lower lobe.

DISCUSSION

Pulmonary sequestration is a congenital malformation where aberrant lung tissue which has no connection to the bronchial tree or pulmonary arteries. It has its own blood supply usually from the descending aorta like this case or it may arise from one of the upper abdominal aortic branches. It may have its own pleural envelope or be enveloped in the lung pleura, in which case it would be termed extra-lobar or intra-lobar respectively. Venous drainage patterns differ between the two where intra-lobar sequestration has its venous drainage through the pulmonary venous system and extra-lobar sequestration has its venous drainage through the systemic venous circulation, usually the azygous system. Intra-lobar sequestration is more common and typically is found in adult life due to recurrent infections. Extra-lobar can be picked up in utero as a pulmonary mass and depending on the size may require neonatal surgical intervention. An important differential diagnosis is neuroblastoma which can present in the same location in the neonatal period. CT and MRI are useful diagnostic tools to identify the feeding artery and high quality multiplanar reformat and three dimensional reconstructions can utilized for pre-surgical planning to determine the internal architecture of the malformed tissue.

REFERENCES

1. McLoud Theresa C, Boiselle Phillip M, Thoracic Radiology: The Requisites, 2nd ed. Philadelphia, PA: Mosby Elsevier, 68 pp., 2010. ISBN: 9780323027908.
2. Biyyam DR, Chapman T, Ferguson MR, Deutsch G, Dighe MK. Congenital lung abnormalities: embryologic features, prenatal diagnosis, and postnatal radiologic-pathologic correlation. Radiographics. 2010 Oct;30(6):1721-38. doi: 10.1148/rg.306105508. PMID: 21071385.

CONTACTS

Mitchell Pearce D.O. PGY-V – mpearce@arnothealth.org

Thomas Taylor M.D. – rads48@aol.com